

## Recommendations for the Endovascular Treatment of Intracranial Aneurysms

### A Statement for Healthcare Professionals from the Committee on Cerebrovascular Imaging of the American Heart Association Council on Cardiovascular Radiology

S. Claiborne Johnston, MD, PhD, Co-Chair; Randall T. Higashida, MD, Co-Chair; Daniel L. Barrow, MD; Louis R. Caplan, MD; Jacques E. Dion, MD; George Hademenos, PhD; L. Nelson Hopkins, MD; Andrew Molyneux, MD; Robert H. Rosenwasser, MD; Fernando Vinuela, MD; Charles B. Wilson, MD

Intracranial aneurysms are common, with a prevalence of 0.5% to 6% in adults, according to angiography and autopsy studies.<sup>1</sup> Most intracranial aneurysms are asymptomatic and are never detected. Some are discovered incidentally in neuroimaging studies and some produce symptoms due to compression of neighboring nerves or adjacent brain tissue. Others are detected only after they have ruptured and caused subarachnoid hemorrhage, a devastating type of stroke associated with 32% to 67% case fatality and 10% to 20% long-term dependence in survivors due to brain damage.<sup>2</sup>

To prevent subarachnoid hemorrhage, physicians have developed methods to treat aneurysms. For ruptured aneurysms, early treatment within 24 to 72 hours has been recommended because the risk of subsequent rupture is high, with approximately 20% risk of rerupture in the first 2 weeks after subarachnoid hemorrhage.<sup>3</sup> Each additional rupture substantially increases the risk of mortality and morbidity. Treatment has also been recommended for most unruptured aneurysms,<sup>4</sup> although there is uncertainty about treatment of some small aneurysms <10 mm because their risk of rupture appears low.<sup>5,6</sup> The American Heart Association formed this special writing group to summarize the literature and create recommendations on endovascular therapy of ruptured and unruptured intracranial aneurysms. This statement is meant to extend previous statements on treatment of subarachnoid hemorrhage<sup>3</sup> and on treatment of unruptured aneurysms.<sup>4</sup> During the review, it became evident that any recommendations would be based primarily on expert opinion weighing evidence only from nonrandomized cohort studies and case series.

### Background

In 1937, Walter Dandy reported the first successful surgical clipping of the neck of an aneurysm. Microsurgical techniques have steadily evolved since then, with development of a variety of surgical approaches and metal aneurysm clips. Repair of aneurysms in nearly all intracranial locations is possible by placing a clip made from a stable metal (including platinum, titanium, tungsten, and steel alloys) across the neck of the aneurysm, thus excluding it from the cerebral circulation.

Endovascular treatment of intracranial aneurysms was first described in the early 1970s by Fedor Serbinenko, a Russian neurosurgeon.<sup>7,8</sup> He used a vascular catheter with a detachable latex balloon to treat aneurysms, either by depositing the balloon directly into the aneurysm lumen or by occluding the artery from which the aneurysm arose.

In 1991, Guido Guglielmi was the first to describe the technique of occluding aneurysms from an endovascular approach with electrolytic detachable platinum coils, termed Guglielmi detachable coils (GDCs).<sup>9,10</sup> GDCs are introduced directly into the aneurysm through a microcatheter and detached from a stainless-steel microguidewire by an electrical current (Figure 1). The aneurysm is packed with 1 or more GDCs, thereby excluding it from the circulation (Figure 2).

As clinical experience with this technique has increased and coil design has improved, coil embolization has been used with increasing frequency even in patients who could be treated by conventional surgical clipping.<sup>11,12</sup> Furthermore, some centers are treating patients with surgical clipping only if they cannot be treated primarily by endovascular coil

---

The American Heart Association makes every effort to avoid any actual or potential conflicts of interest that may arise as a result of an outside relationship or a personal, professional, or business interest of a member of the writing panel. Specifically, all members of the writing group are required to complete and submit a Disclosure Questionnaire showing all such relationships that might be perceived as real or potential conflicts of interest.

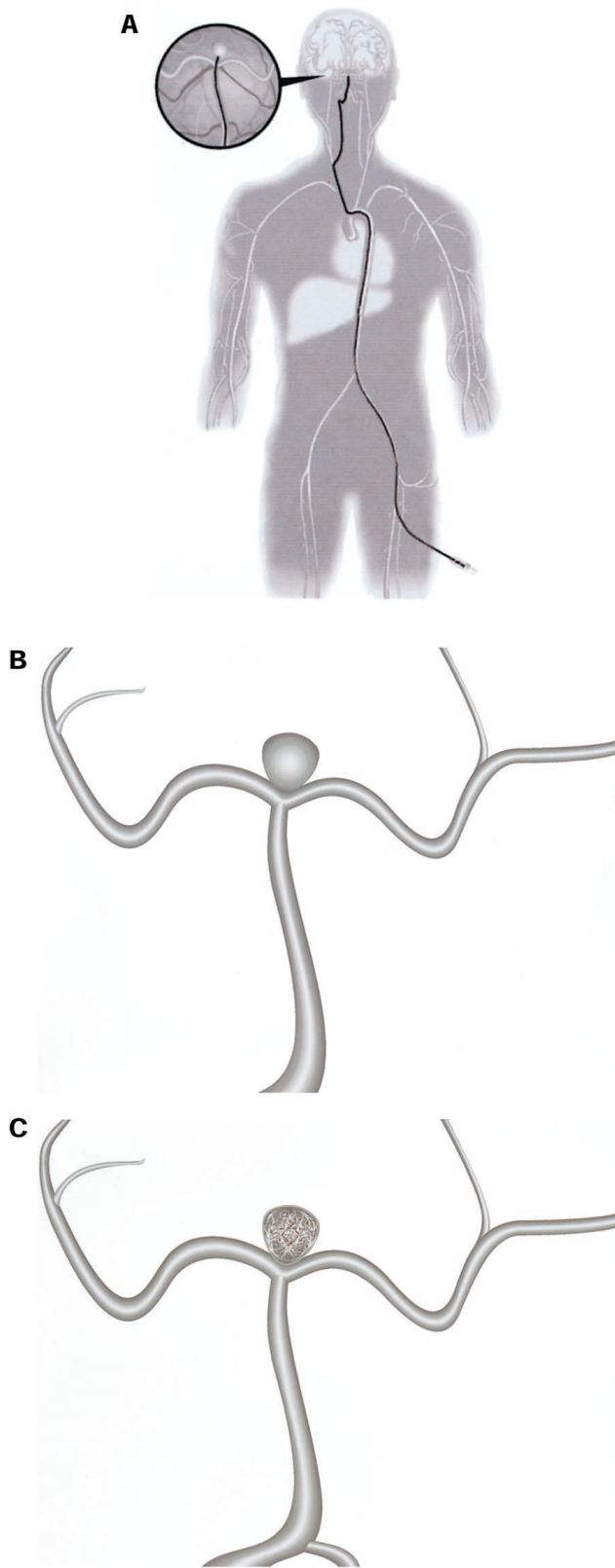
This statement was approved by the American Heart Association Science Advisory and Coordinating Committee in July 2002. A single reprint is available by calling 800-242-8721 (US only) or writing the American Heart Association, Public Information, 7272 Greenville Ave, Dallas, TX 75231-4596. Ask for reprint No. 71-0238. To purchase additional reprints: up to 999 copies, call 800-611-6083 (US only) or fax 413-665-2671; 1000 or more copies, call 410-528-4426, fax 410-528-4264, or e-mail kbradle@lww.com. To make photocopies for personal or educational use, call the Copyright Clearance Center, 978-750-8400.

(*Stroke*. 2002;33:2536-2544.)

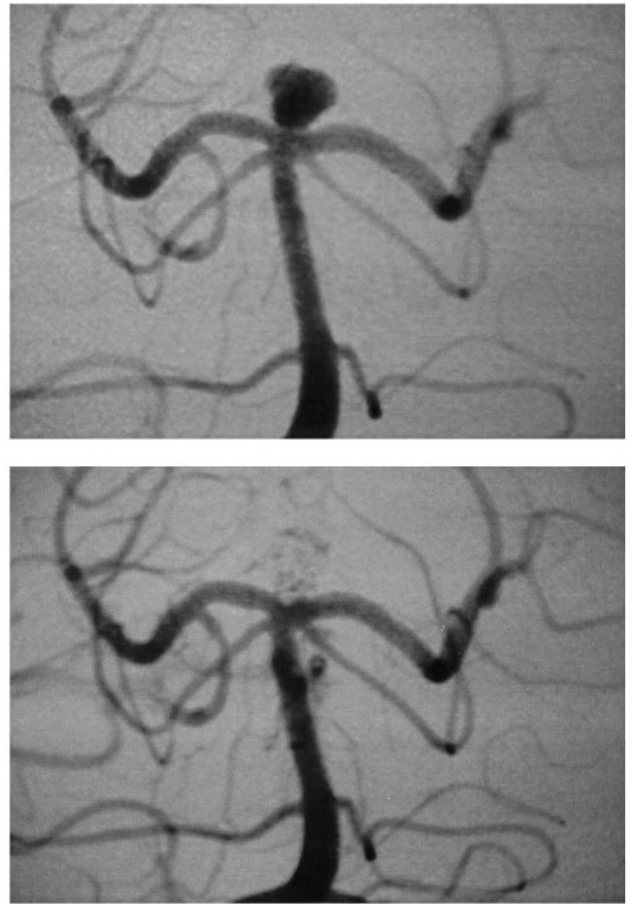
© 2002 American Heart Association, Inc.

*Stroke* is available at <http://www.strokeaha.org>

DOI: 10.1161/01.STR.0000034708.66191.7d



**Figure 1.** Diagram of endovascular treatment of an intracranial aneurysm using detachable coils. (A) A catheter inserted at the femoral artery is advanced to the neck of an aneurysm at the terminus of the basilar artery. (B) Platinum coils are inserted into the aneurysm and detached with complete embolization often requiring multiple coils (C).



**Figure 2.** (A) Anterior-posterior view of angiogram showing an aneurysm at the terminus of the basilar artery. (B) Comparable view after embolization of the aneurysm using detachable platinum coils.

embolization therapy.<sup>13</sup> In August 2002, it was estimated that 100 000 patients with intracranial aneurysms had been treated with GDCs at sites throughout the world, with approximately 1500 patients being treated per month.<sup>14</sup>

Given the wide use of endovascular coil embolization to treat intracranial aneurysms, it is important to establish recommendations, based on the best available evidence, to define appropriate indications for coil embolization and other endovascular techniques in the context of surgical alternatives. The essential elements to compare are risk of morbidity and mortality, and efficacy, measurable in terms of reduced risk of aneurysm rupture after treatment.

### Procedural Risk

Intracranial aneurysm treatment, by either surgery or endovascular coiling, may precipitate a complication that could lead to new symptoms, disability, or death. In comparing procedural risks, a measure of complications caused by the treatment itself would be ideal so that the impact of the therapy could be isolated from other aspects of presentation or medical care. For example, brain injury from subarachnoid hemorrhage at presentation or from aspiration of gastric contents during airway manipulation may lengthen hospitalization or result in disability, and these complications could

obscure the impact of the procedure itself on outcomes. However, determinations of what "procedure-related" means are subjective and require judgment; hence, "measurements" of procedure-related complications are unreliable. In formulating these guidelines, we have favored comparisons of functional outcomes when available in the literature.

Functional outcomes after subarachnoid hemorrhage are highly dependent on the severity of the initial hemorrhage.<sup>15</sup> Although researchers have attempted to adjust for differences in pretreatment prognosis, it is not possible to ensure that adjustment is adequate to compare results in different case series. Thus, comparison of results of case series of procedural risk in ruptured aneurysm treatment should be avoided.

As with all procedures, risk is affected by patient selection, technical expertise, and supportive services, and its measurement is influenced by the definition of the outcome and the judgment of the evaluator. Descriptions of retrospective case series, which dominate the literature on procedural risk of intracranial aneurysm treatment either by surgery or by endovascular coiling, should be considered skeptically given potential sources of bias and will be reviewed only briefly. Comparative studies that include patients treated by both modalities are more likely to assess outcomes impartially and may provide more reliable comparisons of surgery and endovascular coil embolization. Results of randomized trials of adequate size are not currently available.

### **Surgical Series**

A recent meta-analysis of surgery for unruptured intracranial aneurysms included results of 2460 cases described in 61 reports published between January 1966 and June 1996.<sup>16</sup> The mortality rate was 2.6% and permanent morbidity was 10.9%, which was variably defined in the included reports. A large, international prospective study of unruptured aneurysm treatment included 995 surgically treated patients.<sup>5</sup> At 1-year follow-up, surgical mortality was 3.2%. Disability was present in 12.0%: 5.8% had moderate or severe disability and 6.1% had isolated cognitive impairment. Thus, the combined morbidity and mortality rate with surgery for unruptured cerebral aneurysms was 15.2% at 1 year, or 9.0% when limited to moderate disability or worse. Cognitive function has not been measured carefully in other studies.

### **Endovascular Series**

The procedural risk of endovascular coil embolization was recently reviewed in a meta-analysis of case series reported from January 1990 through March 1997.<sup>17</sup> Ninety patients with unruptured aneurysms were included, of whom 73 had follow-up evaluations. The mortality rate was 1.4% and an additional 1.4% had moderate or severe disability, but these rates are unreliable given the small number studied. In addition, 16.7% were noted to have ischemic complications, which resulted in a permanent deficit in 6.7%. The combined permanent morbidity and mortality for endovascular coiling was therefore 8.1%, or 2.8% if limited only to moderate disability or worse. Although a large, international prospective study of unruptured aneurysms included a number of patients treated with coil embolization,<sup>5</sup> results for this

procedure have not been published, and whether coil embolization impacts cognitive function is unknown.

### **Comparative Studies**

No randomized trial of unruptured aneurysm treatment has yet been performed. A single randomized trial comparing the surgical clipping and endovascular coil embolization of ruptured aneurysms has been published, however.<sup>18,19</sup> This single-center study enrolled 109 patients. Outcomes were not significantly different at 3-month and 1-year follow-up, but only an extremely large treatment effect would have been apparent with this small sample size.

The ongoing International Subarachnoid Aneurysm Trial (ISAT), which involves 42 centers in Europe and North America, is expected to complete recruitment of 2500 patients in late 2002.<sup>20</sup> This sample size will be adequate to detect a 25% difference in proportions with moderate or worse disability.

A study of administrative data from 70 academic medical centers in the United States compared treatment risks in 2612 patients treated for unruptured aneurysms from 1994 through 1997.<sup>21</sup> The primary outcome, in-hospital death or discharge to a nursing home or rehabilitation center, was less frequent in those treated with endovascular coil therapy (endovascular 10.6% versus surgery 18.5%;  $P=0.002$ ). In-hospital death was also lower (endovascular 0.4% versus surgery 2.3%;  $P=0.039$ ), but the difference was not significant after adjustment for other prognostic factors.

A similar study of administrative data included 2069 patients with unruptured aneurysms treated in California from 1990 through 1998.<sup>12</sup> Adverse outcomes, defined as in-hospital death or discharge to a nursing home or rehabilitation center, were less frequent in those treated with endovascular therapy (10% versus 25% with surgery;  $P<0.001$ ), as was the risk of in-hospital death (0.5% versus 3.5%;  $P<0.001$ ). These differences persisted after adjustment for other prognostic factors.

A single-center study reported results of 130 patients with unruptured aneurysms who were considered candidates for both surgical clipping and endovascular coil embolization.<sup>11</sup> A change of 2 or more points in the Rankin Scale, indicative of a new moderate disability or worse,<sup>22</sup> occurred in 8% of cases treated with endovascular therapy and in 25% of cases treated by surgical clipping ( $P=0.01$ ). Practitioners blinded to actual treatment and outcome judged pretreatment risks within the 2 groups to be comparable.

Another single-center study compared surgery and endovascular therapy of ruptured and unruptured basilar terminus aneurysms in 41 patients who were considered candidates for either procedure.<sup>23</sup> Only 15 patients were treated for unruptured aneurysms, and outcome differences did not reach significance.

No difference in overall outcome was detected after the introduction of coil embolization as a treatment option for intracranial aneurysms at a single center.<sup>24</sup> However, 2 studies of administrative data have shown improved outcomes for intracranial aneurysm treatment at hospitals that use endovascular therapy in a larger portion of patients.<sup>12,25</sup>

**Procedural Efficacy: Studies Measuring Rerupture Rates From Treated Ruptured Aneurysms**

Studies	Subjects	Average Follow-Up, y	Annual Rerupture Rate, %	Comments
<b>Surgery</b>				
Koivisto et al (2000) <sup>18</sup>	57	1	0	Two intraoperative ruptures.
David et al (1999) <sup>26</sup>	62 (+40 unruptured)	0.7	0.3	Did not report rate in previously ruptured aneurysms separately; rate was 1.5%/y for incompletely occluded.
Tsutsumi et al (1998) <sup>27</sup>	220 (completely occluded)	11	0.2	Did not report rate in those with incomplete aneurysm occlusion.
Yoshimoto et al (1979) <sup>28</sup>	876	3.6	0.1 (mortality)	Unclear whether nonfatal reruptures were recorded.
<b>Endovascular therapy</b>				
Koivisto et al (2000) <sup>18</sup>	52	1	1.9	Single rerupture within 24 hours after incomplete occlusion.
Byrne et al (1999) <sup>39</sup>	317	1.8	0.6	All reruptures occurred in incompletely occluded aneurysms.
Cognard et al (1998) <sup>40</sup>	150	0.8	0.9	
Uda et al (1998) <sup>41</sup>	7	1.5	0	
Graves et al (1995) <sup>42</sup>	10	1.3	0	
Casasco et al (1993) <sup>43</sup>	67	0.5	3.0	Single rerupture after incomplete occlusion.

**Conclusions**

Observational studies provide the only useful information about the relative risks of surgery and endovascular coil embolization in the treatment of ruptured and unruptured intracranial aneurysms. Although most comparative studies have suggested that coil embolization is safer, others have not, and all studies are limited by the possibility that patient selection is contributing to outcome differences.

**Procedural Efficacy**

The primary goal of any treatment for intracranial aneurysms is to reduce the risk of initial or recurrent subarachnoid hemorrhage; therapies for repair of either ruptured or unruptured aneurysms are based on this principle. The appearance of a fully occluded aneurysm after its treatment should not be considered a reliable surrogate for risk of subsequent aneurysm rupture without clear evidence correlating the degree of occlusion with subsequent rupture rates: complete occlusion may not be required to reduce rupture rates or may not be adequate. Furthermore, some unruptured aneurysms are at low risk of rupture when left untreated.<sup>5</sup> Therefore, efficacy of therapy may be evaluated most efficiently by comparing subarachnoid hemorrhage rates after treatment of ruptured aneurysms. Short-term reductions in rerupture rates may not persist, so it is important to evaluate long-term risks. Calculation of the rate requires a tally of the number of new events and of the total person-years of follow-up observation, which has been reported in only a small number of studies (Table).

**Surgical Clipping**

Three studies have reported rates of rerupture after surgical clipping of ruptured aneurysms<sup>18,26,27</sup> and 1 other reported mortality from rerupture.<sup>28</sup> In a recent review of the literature on aneurysm growth and hemorrhage after surgical clipping of ruptured and unruptured aneurysms, there were 6 hemorrhages after treatment of 1397 patients, but duration of

follow-up was not reported.<sup>29</sup> One small series of distal basilar artery aneurysms<sup>23</sup> documented no reruptures in surgically clipped aneurysms during 32.5 patient-years of follow-up. Other reports have documented subarachnoid hemorrhage after surgical clipping of previously ruptured aneurysms but did not provide adequate detail to determine annual rates of rupture.<sup>30–38</sup>

**Coil Embolization**

Several case series have documented rates of subarachnoid hemorrhage after coil embolization of ruptured aneurysms. Six studies included ruptured aneurysms in all locations and provide adequate information to calculate annual rerupture rates (Table).<sup>18,39–43</sup> Combining these 6 studies, a rerupture rate of 0.9% per year is estimated after coil embolization of ruptured aneurysms in various locations.

Four studies have provided detailed information on hemorrhage after coil embolization of ruptured aneurysms arising from the posterior circulation. In a study of 34 ruptured distal basilar artery aneurysms, there was a single rerupture of an incompletely occluded aneurysm during 74.8 patient-years of follow-up, corresponding to a rate of 1.3% per year.<sup>44</sup> Another study of 61 patients, who were followed for a mean of 1.1 years after treatment, found an annual rerupture rate of 2.9%.<sup>45</sup> Another study documented no reruptures during approximately 24 patient-years of follow-up.<sup>23</sup> A study that included 104 patients with ruptured posterior circulation aneurysms documented a single rerupture, with an annual rate of 0.9%.<sup>46</sup> Combining these studies, a 1.4% annual rerupture rate is estimated for aneurysms arising from the posterior circulation, primarily from the distal basilar artery.

Several series have noted that larger aneurysms were more likely to recur and present with hemorrhage after treatment. In a cohort study of previously ruptured aneurysms more than 2 cm in diameter, 1 rerupture occurred in 36.6 patient-years of follow-up, corresponding to an annual rupture rate of 2.7%.<sup>47</sup>



Other case series have noted subarachnoid hemorrhages during long-term follow-up after coil embolization, but either have not provided length of follow-up or have not distinguished between ruptured and unruptured aneurysms at the time of initial treatment.<sup>48-57</sup> Therefore, it is not possible to calculate rates of rerupture from this group of publications. In 1 of these reports, an overall annual hemorrhage rate of 1.8% was reported after coil embolization in a consecutive series of ruptured and unruptured aneurysms.<sup>49</sup> Aneurysm size was an important predictor of hemorrhage risk, with 33% of giant aneurysms, 4% of large aneurysms, and no small aneurysms presenting with new hemorrhage during an average of 3.5 years' follow-up. Another similar series found an overall annual hemorrhage rate of 1.4% over 141 patient-years, with degree of occlusion an important predictor.<sup>56</sup>

### Occlusion Rates

Case reports and series have shown that even aneurysms that appear completely occluded after surgery or endovascular coil embolization may later rupture.<sup>26,48,58</sup> However, the majority of hemorrhages after treatment reported in patients with postprocedural angiography have occurred in incompletely occluded aneurysms, and aneurysm growth appears to be more frequent when complete occlusion is not achieved, with an incidence of 49% in 1 series of 178 incompletely occluded aneurysms.<sup>59</sup> Angiographic follow-up may reveal return of blood flow into an aneurysm and provide an opportunity to further treat an aneurysm before it becomes symptomatic.<sup>59,60</sup> Therefore, although the degree of aneurysm obliteration does not appear to be an adequate surrogate for hemorrhage risk after treatment, it may be an important goal of treatment by both endovascular coil embolization and surgical clipping.

Complete occlusion is not possible on first endovascular treatment in a significant portion of intracranial aneurysms.<sup>17</sup> In meta-analysis, only 54% of aneurysms were completely occluded after initial coil embolization, with 88% more than 90% occluded.<sup>17</sup> Follow-up angiography and additional coil embolization are required to completely occlude many aneurysms by endovascular means. Coils in an incompletely treated aneurysm may make it more difficult to obtain complete occlusion with surgical clipping. Complications and inconveniences of follow-up care should therefore be considered in making treatment decisions and in comparing outcomes of procedures.

### Compressive Symptoms

Although reduction of risk of rupture is the primary reason for intracranial aneurysm treatment, relief of symptoms due to mass effect may also be important. Coil embolization relieved symptoms and signs of mass effect in more than 90% of cases in a series of 26 patients.<sup>61</sup> However, improvements were less dramatic in a second series of 16 patients with aneurysms compressing cranial nerves, in which coil embolization resulted in improvement in 74% and worsening in 5%.<sup>62</sup>

### Conclusions

All reported series of long-term follow-up after coil embolization or surgical clipping of intracranial aneurysms are

likely to contain biases. Because sudden death is common after subarachnoid hemorrhage and cause of death may go undiagnosed, true hemorrhage rates are likely higher than those reported in the literature. In addition, efforts to obtain follow-up information on all treated patients have been variable.

Rates of rerupture in untreated ruptured aneurysms are high, with studies documenting 20% to 30% risk in the first month and approximately 3% per year thereafter.<sup>3</sup> Both surgical clipping and endovascular coil embolization appear to reduce this risk, but evidence is sparse in the delayed period. Further studies with long-term follow-up are required to compare the efficacy of these procedures.

### Therapy Selection

Selection of endovascular coil embolization or surgery for a particular patient should depend on an individualized determination of relative risks and likelihood of complete occlusion. Characteristics of the aneurysm and patient may influence the final treatment decision. Other key factors are the location of the aneurysm and its size, and contraindications to radiographic contrast, such as known allergy or renal failure.

### Aneurysm Location

Middle cerebral artery aneurysms are frequently difficult to treat by coil embolization,<sup>11,13,63</sup> and surgical results for these aneurysms are often reported as more favorable than in other locations.<sup>28,64,65</sup> Aneurysms in the posterior cerebral circulation, however, are difficult to treat with surgery,<sup>16</sup> and comparative observational studies have found better outcomes after coil embolization in these locations.<sup>11,23</sup> Aneurysms in the cavernous segment of the internal carotid artery are also difficult to treat with surgery<sup>66</sup> but may be relatively easily treated with coil embolization,<sup>67</sup> and both treatments can lead to reduction in compressive symptoms.<sup>61</sup>

### Aneurysm Size

For both surgery and endovascular therapy, aneurysm size has been associated with an increase in risk of complications and a decreased likelihood of complete occlusion. The risks of disability and mortality with surgery versus endovascular coiling were greater for giant aneurysms >25 mm in a meta-analysis of studies of unruptured aneurysms.<sup>16</sup> A similar association has been reported in some series of aneurysms treated by coil embolization.<sup>68,69</sup> Complete occlusion is less frequently obtainable for larger aneurysms, and additional embolizations are often required during follow-up.<sup>40,47,51,70</sup> Very small aneurysms, such as those with diameter <3 mm, are also difficult to treat by coil embolization, and intraoperative rupture may be more frequent.<sup>48</sup> However, comparative studies have not evaluated the impact of size on outcomes.

In several studies, aneurysm neck size has been a predictor of the likelihood of complete occlusion by coil embolization, particularly when considered relative to the size of the aneurysm.<sup>70-73</sup> A neck diameter of <5 mm and a ratio of neck diameter to largest aneurysm dimension of <0.5 have been associated with better outcomes, in terms of both rates of complications and likelihood of complete occlusion by coil embolization.<sup>71</sup> In studies of surgical outcomes, neck size has

not been reported as an independent predictor of successful clipping or outcomes.

### Comorbid Medical Conditions

Comorbid medical conditions and complications from an initial subarachnoid hemorrhage may also influence the selection of surgery or endovascular therapy. For example, the presence of a large parenchymal hematoma with mass effect may favor a decision to perform open surgery to reduce intracranial pressure by surgical evacuation of the hematoma. By contrast, a poor Hunt-Hess grade or evidence of significant brain swelling without a mass lesion may increase the risk of surgical retraction<sup>74</sup> but has less influence on the difficulty of coil embolization treatment.<sup>75</sup>

### Technological Advances

Advances in technology are likely to alter the proportion of aneurysms that are treatable by endovascular techniques. Advances in coil technology—such as the introduction of coils with complex shapes and 3-dimensional structures, ultrasoft coils,<sup>76</sup> and liquid polymer techniques<sup>77</sup>—and development of techniques using balloons<sup>78–82</sup> and intravascular stents<sup>83–90</sup> to support coil occlusion are examples of improvements that have broadened the appropriate indications for coil embolization. Improvements in surgical equipment and techniques have also occurred in the last decade<sup>1</sup> and are likely to continue.

The skills of the treating practitioner and institution are important. Outcomes of endovascular coil embolization improve with the experience of the practitioners,<sup>49</sup> and a similar association is likely with surgery.<sup>91</sup> In studies of administrative data, institutions that treated a greater number of intracranial aneurysms had better outcomes,<sup>12,91</sup> and outcomes improved in more recent years.<sup>12</sup>

Selecting appropriate candidates for surgery and endovascular coil embolization is a complex process that involves integration of information about the patient's medical condition, the aneurysm's characteristics, evolving techniques and equipment, and the skills and experience of available practitioners.

### Follow-Up Imaging After Coil Embolization

An aneurysm may grow or recanalize after coil embolization.<sup>17</sup> This may occur even in aneurysms that appear completely occluded after initial treatment.<sup>48,58</sup> Further embolization is possible and may be required to prevent growth and potential subarachnoid hemorrhage.<sup>59,60</sup>

Follow-up imaging provides an opportunity to identify inadequately treated aneurysms before subarachnoid hemorrhage or other symptoms occur. A variable number of aneurysms will require additional treatment after initial coil embolization. When completion of treatment is not possible with coil embolization, surgery may be indicated.<sup>92</sup>

No data are available to define the appropriate timing of follow-up imaging. After apparent complete occlusion, many practitioners prescribe a follow-up angiogram at 6 months, with additional follow-up imaging based on aneurysm appearance. If complete occlusion is not possible, follow-up imaging is often obtained more frequently.

Catheter angiography has been the preferred imaging modality for follow-up after coil embolization. Given the small risk of permanent complications with catheter angiography—recently estimated as <0.1% in this setting<sup>93,94</sup>—and its cost, a noninvasive screening test to identify patients with recanalization after coil embolization is highly desirable but is complicated by the characteristics of the platinum coils. Although MR angiography can identify a residual aneurysmal neck,<sup>95</sup> platinum coils are associated with artifacts that preclude reliable imaging of treated aneurysms with MR and CT angiography. Plain skull x-rays may identify patients with aneurysm recanalization. In a study of 82 treated aneurysms, evidence of coil compaction on skull x-rays identified all patients who were confirmed to have return of flow into an aneurysm by angiography.<sup>96</sup> No other studies have tested the reliability of skull x-rays in this setting.

### Indications for Parent Artery Occlusion

An intracranial aneurysm can be treated by occluding the parent artery—the artery from which it arises. However, occlusion of intracranial arteries may lead to ischemia. The ischemic consequences of parent artery occlusion can be predicted by temporarily inflating a balloon to occlude the vessel and evaluating effects on brain function and hemodynamics.<sup>97–99</sup> However, ischemic sequelae may still occur even in those who tolerate a test occlusion,<sup>98,99</sup> even if an extracranial-to-intracranial arterial bypass is performed.<sup>100</sup>

Parent arteries can be occluded using surgical clips or using endovascular techniques. Endovascular occlusion can be performed simply, as an extension of a test occlusion. Compressive symptoms from the aneurysm are often relieved after parent artery occlusion,<sup>101,102</sup> presumably by reducing the pressure and by retraction of any blood clot within the aneurysm. This approach has been used most commonly for aneurysms that cannot be treated by direct surgical clipping or coil embolization when the risk of not treating is very high.<sup>101,102</sup>

### Recommendations

Given the absence of data from randomized trials, all recommendations are based on expert opinion. Endovascular coil embolization is an option for treatment of ruptured and unruptured intracranial aneurysms. Special consideration for coil embolization should be given when surgery is impossible or is high risk. This may include patients with aneurysms in the posterior circulation. Results of a randomized trial are required to define the appropriate role of endovascular coil embolization in the treatment of patients who are candidates for surgery.

Endovascular occlusion of the artery from which an aneurysm arises is a treatment option when an aneurysm cannot be treated directly with surgery or endovascular coil embolization and when that aneurysm is at high risk for subsequent rupture or when neurological symptoms are progressive.

All patients whose aneurysms are treated by coil embolization should have follow-up catheter angiography performed 1 to 6 months after initial treatment. Follow-up imaging should occur sooner in patients with aneurysms that are not completely occluded. Subsequent angiography should be

performed in patients whose aneurysms remain incompletely occluded.

## Synthesis and Conclusions

The current literature on endovascular therapy consists of reports of cohort studies, case series, and 1 pilot randomized trial, so evidence about the role of endovascular therapy of intracranial aneurysms is limited. Although the literature suggests that endovascular therapy has an important role in treating aneurysms that are difficult to treat by surgery, results of a randomized trial are necessary to establish the relative indications of these 2 approaches.

## References

- Schievink WI. Intracranial aneurysms. *N Engl J Med*. 1997;336:28–40.
- Hop JW, Rinkel GJ, Algra A, van Gijn J. Case-fatality rates and functional outcome after subarachnoid hemorrhage: a systematic review. *Stroke*. 1997;28:660–664.
- Mayberg MR, Batjer HH, Dacey R, Diringer M, Haley EC, Heros RC, Sternau LL, Torner J, Adams HP Jr, Feinberg W, et al. Guidelines for the management of aneurysmal subarachnoid hemorrhage: a statement for healthcare professionals from a special writing group of the Stroke Council, American Heart Association. *Stroke*. 1994;25:2315–2328.
- Bederson JB, Awad IA, Wiebers DO, Piepgras D, Haley EC, Brott T, Hademenos G, Chyatte D, Rosenwasser R, Caoselli C. Recommendations for the management of patients with unruptured intracranial aneurysms. *Circulation*. 2000;102:2300–2308.
- International Study of Unruptured Intracranial Aneurysms Investigators. Unruptured intracranial aneurysms: risk of rupture and risks of surgical intervention. *N Engl J Med*. 1998;339:1725–1733.
- Johnston SC, Gress DR, Kahn JG. Which unruptured cerebral aneurysms should be treated? A cost-utility analysis. *Neurology*. 1999;52:1806–1815.
- Serbinenko FA. [Catheterization, and occlusion of major cerebral vessels and prospects for the development of vascular neurosurgery]. *Vopr Neurokhir*. 1971;35:17–27.
- Serbinenko FA. Balloon catheterization and occlusion of major cerebral vessels. *J Neurosurg*. 1974;41:125–145.
- Guglielmi G, Vinuela F, Dion J, Duckwiler G. Electrothrombosis of saccular aneurysms via endovascular approach, part 2: preliminary clinical experience. *J Neurosurg*. 1991;75:8–14.
- Guglielmi G, Vinuela F, Sepetka I, Macellari V. Electrothrombosis of saccular aneurysms via endovascular approach, part 1: electrochemical basis, technique, and experimental results. *J Neurosurg*. 1991;75:1–7.
- Johnston SC, Wilson CB, Halbach VV, Higashida RT, Dowd CF, McDermott MW, Applebury CB, Farley TL, Gress DR. Endovascular and surgical treatment of unruptured cerebral aneurysms: comparison of risks. *Ann Neurol*. 2000;48:11–19.
- Johnston SC, Zhao S, Dudley RA, Berman MF, Gress DR. Treatment of unruptured cerebral aneurysms in California. *Stroke*. 2001;32:597–605.
- Raftopoulos C, Mathurin P, Boscherini D, Billa RF, Van Boven M, Hantson P. Prospective analysis of aneurysm treatment in a series of 103 consecutive patients when endovascular embolization is considered the first option. *J Neurosurg*. 2000;93:175–182.
- Hopkins LN, Lanzino G, Guterman LR. Treating complex nervous system vascular disorders through a “needle stick”: origins, evolution, and future of neuroendovascular therapy. *Neurosurgery*. 2001;48:463–475.
- Hunt WE, Hess RM. Surgical risk as related to time of intervention in the repair of intracranial aneurysms. *J Neurosurg*. 1968;28:14–20.
- Raaymakers TW, Rinkel GJ, Limburg M, Algra A. Mortality and morbidity of surgery for unruptured intracranial aneurysms: a meta-analysis. *Stroke*. 1998;29:1531–1538.
- Brilstra EH, Rinkel GJE, van der Graaf Y, van Rooij WJJ, Algra A. Treatment of intracranial aneurysms by embolization with coils: a systematic review. *Stroke*. 1999;30:470–476.
- Koivisto T, Vanninen R, Hurskainen H, Saari T, Hernesniemi J, Vapalahti M. Outcomes of early endovascular versus surgical treatment of ruptured cerebral aneurysms: a prospective randomized study. *Stroke*. 2000;31:2369–2377.
- Vanninen R, Koivisto T, Saari T, Hernesniemi J, Vapalahti M. Ruptured intracranial aneurysms: acute endovascular treatment with electrolytically detachable coil: a prospective randomized study. *Radiology*. 1999;211:325–336.
- Molyneux A, Kerr R. International subarachnoid aneurysm trial. *J Neurosurg*. 1999;91:352–353.
- Johnston SC, Dudley RA, Gress DR, Ono L. Surgical and endovascular treatment of unruptured cerebral aneurysms at university hospitals. *Neurology*. 1999;52:1799–1805.
- Rankin J. Cerebral vascular accidents in patients over the age of 60, II: prognosis. *Scot Med J*. 1957;2:200–215.
- Gruber DP, Zimmerman GA, Tomsick TA, van Loveren HR, Link MJ, Tew JM Jr. A comparison between endovascular and surgical management of basilar artery apex aneurysms. *J Neurosurg*. 1999;90:868–874.
- Sturaitis MK, Rinne J, Chaloupka JC, Kaynar M, Lin ZQ, Awad IA. Impact of Guglielmi detachable coils on outcomes of patients with intracranial aneurysms treated by a multidisciplinary team at a single institution. *J Neurosurg*. 2000;93:569–580.
- Johnston SC. Effect of endovascular services and hospital volume on cerebral aneurysm treatment outcomes. *Stroke*. 2000;31:111–117.
- David CA, Vishteh AG, Spetzler RF, Lemole M, Lawton MT, Partovi S. Late angiographic follow-up review of surgically treated aneurysms. *J Neurosurg*. 1999;91:396–401.
- Tsutsumi K, Ueki K, Usui M, Kwak S, Kirino T. Risk of recurrent subarachnoid hemorrhage after complete obliteration of cerebral aneurysms. *Stroke*. 1998;29:2511–2513.
- Yoshimoto T, Uchida K, Kaneko U, Kayama T, Suzuki J. An analysis of follow-up results of 1000 intracranial saccular aneurysms with definitive surgical treatment. *J Neurosurg*. 1979;50:152–157.
- Thornton J, Bashir Q, Aletich VA, Debrun GM, Ausman JI, Charbel FT. What percentage of surgically clipped intracranial aneurysms have residual necks? *Neurosurgery*. 2000;46:1294–1298.
- Proust F, Toussaint P, Hannequin D, Rabenoïna C, Le Gars D, Fréger P. Outcome in 43 patients with distal anterior cerebral artery aneurysms. *Stroke*. 1997;28:2405–2409.
- Olafsson E, Hauser WA, Gudmundsson G. A population-based study of prognosis of ruptured cerebral aneurysm: mortality and recurrence of subarachnoid hemorrhage. *Neurology*. 1997;48:1191–1195.
- Macdonald RL, Wallace MC, Kestle JR. Role of angiography following aneurysm surgery. *J Neurosurg*. 1993;79:826–832.
- Rauzzino MJ, Quinn CM, Fisher WS 3rd. Angiography after aneurysm surgery: indications for “selective” angiography. *Surg Neurol*. 1998;49:32–40.
- Feuerberg I, Lindquist C, Lindqvist M, Steiner L. Natural history of postoperative aneurysm rests. *J Neurosurg*. 1987;66:30–34.
- Lin T, Fox AJ, Drake CG. Regrowth of aneurysm sacs from residual neck following aneurysm clipping. *J Neurosurg*. 1989;70:556–560.
- Ebina K, Suzuki M, Andoh A, Saitoh K, Iwabuchi T. Recurrence of cerebral aneurysm after initial neck clipping. *Neurosurgery*. 1982;11:764–768.
- Sakaki T, Takeshima T, Tominaga M, Hashimoto H, Kawaguchi S. Recurrence of ICA-PCoA aneurysms after neck clipping. *J Neurosurg*. 1994;80:58–63.
- Drake CG, Vanderlinden RG. The late consequences of incomplete surgical treatment of cerebral aneurysms. *J Neurosurg*. 1967;27:226–238.
- Byrne JV, Sohn MJ, Molyneux AJ, Chir B. Five-year experience in using coil embolization for ruptured intracranial aneurysms: outcomes and incidence of late rebleeding. *J Neurosurg*. 1999;90:656–663.
- Cognard C, Weill A, Castaing L, Rey A, Moret J. Intracranial berry aneurysms: angiographic and clinical results after endovascular treatment. *Radiology*. 1998;206:499–510.
- Uda K, Goto K, Ogata N, Izumi N, Nagata S, Matsuno H. Embolization of cerebral aneurysms using Guglielmi detachable coils: problems and treatment plans in the acute stage after subarachnoid hemorrhage and long-term efficiency. *Neurol Med Chir (Tokyo)*. 1998;38:143–152.
- Graves VB, Strother CM, Duff TA, Perl J 2nd. Early treatment of ruptured aneurysms with Guglielmi detachable coils: effect on subsequent bleeding. *Neurosurgery*. 1995;37:640–647.
- Casasco AE, Aymard A, Gobin YP, Houdart E, Rogopoulos A, George B, Hodes JE, Cophignon J, Merland JJ. Selective endovascular treatment of 71 intracranial aneurysms with platinum coils. *J Neurosurg*. 1993;79:3–10.



44. Bavinski G, Killer M, Gruber A, Reinprecht A, Gross CE, Richling B. Treatment of basilar artery bifurcation aneurysms by using Guglielmi detachable coils: a 6-year experience. *J Neurosurg.* 1999;90:843–852.
45. Eskridge JM, Song JK. Endovascular embolization of 150 basilar tip aneurysms with Guglielmi detachable coils: results of the Food and Drug Administration multicenter clinical trial. *J Neurosurg.* 1998;89:81–86.
46. Lempert TE, Malek AM, Halbach VV, Phatouros CC, Meyers PM, Dowd CF, Higashida RT. Endovascular treatment of ruptured posterior circulation cerebral aneurysms: clinical and angiographic outcomes. *Stroke.* 2000;31:100–110.
47. Gruber A, Killer M, Bavinski G, Richling B. Clinical and angiographic results of endosaccular coiling treatment of giant and very large intracranial aneurysms: a 7-year, single-center experience. *Neurosurgery.* 1999;45:793–803.
48. Raymond J, Roy D. Safety and efficacy of endovascular treatment of acutely ruptured aneurysms. *Neurosurgery.* 1997;41:1235–1245.
49. Malisch TW, Guglielmi G, Vinuela F, Duckwiler G, Gobin YP, Martin NA, Frazee JG. Intracranial aneurysms treated with the Guglielmi detachable coil: midterm clinical results in a consecutive series of 100 patients. *J Neurosurg.* 1997;87:176–183.
50. Murayama Y, Viñuela F, Duckwiler GR, Gobin YP, Guglielmi G. Embolization of incidental cerebral aneurysms by using the Guglielmi detachable coil system. *J Neurosurg.* 1999;90:207–214.
51. Vinuela F, Duckwiler G, Mawad M. Guglielmi detachable coil embolization of acute intracranial aneurysm: perioperative anatomical and clinical outcome in 403 patients. *J Neurosurg.* 1997;86:475–482.
52. Guglielmi G, Vinuela F, Duckwiler G, Dion J, Lylyk P, Berenstein A, Strother C, Graves V, Halbach V, Nichols D, Hopkins N, Ferguson R, Sepetka I. Endovascular treatment of posterior circulation aneurysms by electrothrombolysis using electrically detachable coils. *J Neurosurg.* 1992;77:515–524.
53. Makoui AS, Smith DA, Evans AJ, Cahill DW. Early aneurysm recurrence after technically satisfactory Guglielmi detachable coil therapy: is early surveillance needed? Case report. *J Neurosurg.* 2000;92:355–358.
54. Manabe H, Fujita S, Hatayama T, Suzuki S, Yagihashi S. Rerupture of coil-embolized aneurysm during long-term observation: case report. *J Neurosurg.* 1998;88:1096–1098.
55. Holley P, Bonafé A, Cha F, Arrué P, Maillard A, Sabatier J, Boetto S, Delisle MB, Tremoulet M, Manelfe C. Complications of the intravascular treatment of intracranial aneurysms using metal microcoils: embolization using coils in intracranial aneurysms. *J Neuroradiol.* 1994;21:205–212.
56. Kuether TA, Nesbit GM, Barnwell SL. Clinical and angiographic outcomes, with treatment data, for patients with cerebral aneurysms treated with Guglielmi detachable coils: a single-center experience. *Neurosurgery.* 1998;43:1016–1025.
57. Tateshima S, Murayama Y, Gobin YP, Duckwiler GR, Guglielmi G, Viñuela F. Endovascular treatment of basilar tip aneurysms using Guglielmi detachable coils: anatomic and clinical outcomes in 73 patients from a single institution. *Neurosurgery.* 2000;47:1332–1339.
58. Mawad M. Subarachnoid hemorrhage due to late recurrence of a previously unruptured aneurysm after complete endovascular occlusion. *Am J Neuroradiol.* 1998;19:1810–1811.
59. Hayakawa M, Murayama Y, Duckwiler GR, Gobin YP, Guglielmi G, Viñuela F. Natural history of the neck remnant of a cerebral aneurysm treated with the Guglielmi detachable coil system. *J Neurosurg.* 2000;93:561–568.
60. Mericle RA, Wakhloo AK, Lopes DK, Lanzio G, Guterman LR, Hopkins LN. Delayed aneurysm regrowth and recanalization after Guglielmi detachable coil treatment: case report. *J Neurosurg.* 1998;89:142–145.
61. Halbach VV, Higashida RT, Dowd CF, Barnwell SL, Fraser KW, Smith TP, Teitelbaum GP, Hieshima GB. The efficacy of endosaccular aneurysm occlusion in alleviating neurological deficits produced by mass effect. *J Neurosurg.* 1994;80:659–666.
62. Malisch TW, Guglielmi G, Vinuela F, Duckwiler G, Gobin YP, Martin NA, Frazee JG, Chmiel JS. Unruptured aneurysms presenting with mass effect symptoms: response to endosaccular treatment with Guglielmi detachable coils, part I: symptoms of cranial nerve dysfunction. *J Neurosurg.* 1998;89:956–961.
63. Regli L, Uske A, de Tribolet N. Endovascular coil placement compared with surgical clipping for the treatment of unruptured middle cerebral artery aneurysms: a consecutive series. *J Neurosurg.* 1999;90:1025–1030.
64. Khanna RK, Malik GM, Qureshi N. Predicting outcome following surgical treatment of unruptured intracranial aneurysms: a proposed grading system. *J Neurosurg.* 1996;84:49–54.
65. Rinne J, Hernesniemi J, Niskanen M, Vapalahti M. Analysis of 561 patients with 690 middle cerebral artery aneurysms: anatomic and clinical features as correlated to management outcome. *Neurosurgery.* 1996;38:2–11.
66. Diaz FG, Ohaegbulam S, Dujovny M, Ausman JI. Surgical management of aneurysms in the cavernous sinus. *Acta Neurochir (Wien).* 1988;91:25–28.
67. Halbach VV, Higashida RT, Dowd CF, Urwin RW, Balousek PA, Lempert TE, Hieshima GB. Cavernous internal carotid artery aneurysms treated with electrolytically detachable coils. *J Neuroophthalmol.* 1997;17:231–239.
68. Casasco A, George B. Endovascular treatment of saccular intracranial aneurysm. *J Neurosurg Sci.* 1998;42:125–126.
69. McDougall CG, Halbach VV, Dowd CF, Higashida RT, Larsen DW, Hieshima GB. Endovascular treatment of basilar tip aneurysms using electrolytically detachable coils. *J Neurosurg.* 1996;84:393–399.
70. Turjman F, Massoud TF, Sayre J, Viñuela F. Predictors of aneurysmal occlusion in the period immediately after endovascular treatment with detachable coils: a multivariate analysis. *AJNR Am J Neuroradiol.* 1998;19:1645–1651.
71. Debrun GM, Aletich VA, Kehrli P, Misra M, Ausman JI, Charbel F. Selection of cerebral aneurysms for treatment using Guglielmi detachable coils: the preliminary University of Illinois at Chicago experience. *Neurosurgery.* 1998;43:1281–1295.
72. Hope JKA, Byrne JV, Molyneux AJ. Factors influencing successful angiographic occlusion of aneurysms treated by coil embolization. *Am J Neuroradiol.* 1999;20:391–399.
73. Zubillaga AF, Guglielmi G, Vinuela F, Duckwiler GR. Endovascular occlusion of intracranial aneurysms with electrically detachable coils: correlation of aneurysm neck size and treatment results. *Am J Neuroradiol.* 1994;15:815–820.
74. Yundt KD, Grubb RL Jr, Diringner MN, Powers WJ. Cerebral hemodynamic and metabolic changes caused by brain retraction after aneurysmal subarachnoid hemorrhage. *Neurosurgery.* 1997;40:442–450.
75. Kremer C, Groden C, Hansen HC, Grzycka U, Zeumer H. Outcome after endovascular treatment of Hunt and Hess grade IV or V aneurysms: comparison of anterior versus posterior circulation. *Stroke.* 1999;30:2617–2622.
76. Malek AM, Higashida RT, Phatouros CC, Dowd CF, Halbach VV. Treatment of an intracranial aneurysm using a new three-dimensional-shape Guglielmi detachable coil: technical case report. *Neurosurgery.* 1999;44:1142–1144.
77. Yang X, Wu Z, Li Y, Tang J, Sun Y, Liu Z, Yin K. Re-evaluation of cellulose acetate polymer: angiographic findings and histological studies. *Surg Neurol.* 2001;55:116–122.
78. Moret J, Cognard C, Weill A, Castaings L, Rey A. [Reconstruction technic in the treatment of wide-neck intracranial aneurysms: long-term angiographic and clinical results: apropos of 56 cases]. *J Neuroradiol.* 1997;24:30–44.
79. Levy DI, Ku A. Balloon-assisted coil placement in wide-necked aneurysms: technical note. *J Neurosurg.* 1997;86:724–727.
80. Mericle RA, Wakhloo AK, Rodriguez R, Guterman LR, Hopkins LN. Temporary balloon protection as an adjunct to endosaccular coiling of wide-necked cerebral aneurysms: technical note. *Neurosurgery.* 1997;41:975–978.
81. Aletich VA, Debrun GM, Misra M, Charbel F, Ausman JI. The remodeling technique of balloon-assisted Guglielmi detachable coil placement in wide-necked aneurysms: experience at the University of Illinois at Chicago. *J Neurosurg.* 2000;93:388–396.
82. Malek AM, Halbach VV, Phatouros CC, Lempert TE, Meyers PM, Dowd CF, Higashida RT. Balloon-assist technique for endovascular coil embolization of geometrically difficult intracranial aneurysms. *Neurosurgery.* 2000;46:1397–1406.
83. Higashida RT, Smith W, Gress D, Urwin R, Dowd CF, Balousek PA, Halbach VV. Intravascular stent and endovascular coil placement for a ruptured fusiform aneurysm of the basilar artery: case report and review of the literature. *J Neurosurg.* 1997;87:944–949.
84. Mericle RA, Lanzio G, Wakhloo AK, Guterman LR, Hopkins LN. Stenting and secondary coiling of intracranial internal carotid artery aneurysm: technical case report. *Neurosurgery.* 1998;43:1229–1234.
85. Sekhon LH, Morgan MK, Sorby W, Grinnell V. Combined endovascular stent implantation and endosaccular coil placement for the treatment of



- a wide-necked vertebral artery aneurysm: technical case report. *Neurosurgery*. 1998;43:380–383.
86. Lavine SD, Larsen DW, Giannotta SL, Teitelbaum GP. Parent vessel Guglielmi detachable coil herniation during wide-necked aneurysm embolization: treatment with intracranial stent placement: two technical case reports. *Neurosurgery*. 2000;46:1013–1017.
  87. Lownie SP, Pelz DM, Fox AJ. Endovascular therapy of a large vertebral artery aneurysm using stent and coils. *Can J Neurol Sci*. 2000;27:162–165.
  88. Lylyk P, Ceratto R, Hurvitz D, Basso A. Treatment of a vertebral dissecting aneurysm with stents and coils: technical case report. *Neurosurgery*. 1998;43:385–388.
  89. Wakhloo AK, Lanzino G, Lieber BB, Hopkins LN. Stents for intracranial aneurysms: the beginning of a new endovascular era? *Neurosurgery*. 1998;43:377–379. Editorial; comment.
  90. Phatouros CC, Sasaki TYJ, Higashida RT, Malek AM, Meyers PM, Dowd CF, Halbach VV. Stent-supported coil embolization: the treatment of fusiform and wide-neck aneurysms and pseudoaneurysms. *Neurosurgery*. 2000;47:107–113.
  91. Solomon RA, Mayer SA, Tarmey JJ. Relationship between the volume of craniotomies for cerebral aneurysm performed at New York state hospitals and in-hospital mortality. *Stroke*. 1996;27:13–17.
  92. Thornton J, Dovey Z, Alazzaz A, Misra M, Aletich VA, Debrun GM, Ausman JI, Charbel FT. Surgery following endovascular coiling of intracranial aneurysms. *Surg Neurol*. 2000;54:352–360.
  93. Le Roux PD, Elliott JP, Eskridge JM, Cohen W, Winn HR. Risks and benefits of diagnostic angiography after aneurysm surgery: a retrospective analysis of 597 studies. *Neurosurgery*. 1998;42:1248–1254.
  94. Cloft HJ, Joseph GJ, Dion JE. Risk of cerebral angiography in patients with subarachnoid hemorrhage, cerebral aneurysm, and arteriovenous malformation: a meta-analysis. *Stroke*. 1999;30:317–320.
  95. Derdeyn CP, Graves VB, Turski PA, Masaryk AM, Strother CM. MR angiography of saccular aneurysms after treatment with Guglielmi detachable coils: preliminary experience. *Am J Neuroradiol*. 1997;18:279–286.
  96. Hwang GB, Niimi Y, Setton A, Pryor J, Baltasavias G, Albert R, Hartman J. The accuracy of plain skull x-ray examination as a predictor of recanalization following Guglielmi Detachable Coil embolization in the treatment of cerebral aneurysms. *Intervent Neuroradiol*. 2000;6:195–202.
  97. Cloughesy TF, Nuwer MR, Hoch D, Vinuela F, Duckwiler G, Martin N. Monitoring carotid test occlusions with continuous EEG and clinical examination. *J Clin Neurophysiol*. 1993;10:363–369.
  98. Brunberg JA, Frey KA, Horton JA, Deveikis JP, Ross DA, Koeppe RA. [O-15]H<sub>2</sub>O positron emission tomography determination of cerebral blood flow during balloon test occlusion of the internal carotid artery. *Am J Neuroradiol*. 1994;15:725–732.
  99. Linskey ME, Jungreis CA, Yonas H, Hirsch WL, Sekhar LN, Horton JA, Janosky JE. Stroke risk after abrupt internal carotid artery sacrifice: accuracy of preoperative assessment with balloon test occlusion and stable xenon-enhanced CT. *Am J Neuroradiol*. 1994;15:829–843.
  100. Abruzzo T, Joseph GJ, Owens DS, Dawson RC 3rd, Reid J, Barrow DL. Prevention of complications resulting from endovascular carotid sacrifice: a retrospective assessment. *Neurosurgery*. 2000;46:910–916.
  101. Higashida RT, Halbach VV, Dowd C, Barnwell SL, Dormandy B, Bell J, Hieshima GB. Endovascular detachable balloon embolization therapy of cavernous carotid artery aneurysms: results in 87 cases. *J Neurosurg*. 1990;72:857–863.
  102. Larson JJ, Tew JM, Tomsick TA, Vanloveren HR. Treatment of aneurysms of the internal carotid artery by intravascular balloon occlusion: long-term follow-up of 58 patients. *Neurosurgery*. 1995;36:23–30.

---

KEY WORDS: intracranial aneurysms ■ recommended treatment ■ stroke ■ subarachnoid hemorrhage